Discipline of Oral and Maxillofacial Surgery

3RD YEAR ORAL SURGERY - DEN 318Y

Link to the recorded lecture

https://youtu.be/qJbMTigZepU

Implantology

Implant Site Optimization and Bone Grafting for Implants

Ref:

1. Milloro-Peterson's Principles of Oral and Maxillofacial Surgery. Vol I Ch 12 pp223-234

2. J Hupp, E Ellis III, M Tucker. Contemporary Oral and Maxillofacial Surgery. Ch15: pp266-274

3. 4TH ITI congress, Stuttgart 2008 https://academy.iti.org/my-academy/-/my/consensus-db/1210 and https://academy.iti.org/my-academy/-/my/consensus-db/1211

4. 5Th ITI Congress Bern 2013 https://academy.iti.org/my-academy/-/my/consensus-db/1215

5. 6th ITI Congress Amsterdam 2018 https://academy.iti.org/my-academy/-/my/consensus-db/1814

7. Salvi GE, Monje A, Tomasi C. Long-term biological complications of dental implants placed either in pristine or in augmented sites: A systematic review and meta-analysis. Clin Oral Implants Res. 2018;29:294-310.

6. Handout;

Marco Caminiti
BSc DDS MEd Dip OMFS FRCDC (OMFS)
Assistant Professor
Program Director, Oral and Maxillofacial Surgery
Head, Centre for Corrective Jaw Surgery
University of Toronto

Outline:

1. **Introduction: concepts, principles**
2. **Timing of implants and grafting:**
   i. **Socket preservation**
   ii. **Implant placement with simultaneous grafting**
   iii. **Ridge reconstruction prior to implant placement**
3. **Guided bone graft augmentation/regeneration (GBR)**
4. **Harvesting Bone:**
   i. **Iliac Crest: Anterior, Posterior, Trephine**
   ii. **Costochondral**
   iii. **Intraoral: ramus, symphysis, tuberosity**
   iv. **Tibial Head**
   v. **Calvarium**
   vi. **Other: Platelet Rich Plasma/Traps/Filters/Scrapers**
5. **Mandibular Augmentation**
6. **Maxillary Augmentation**
7. **The Sinus Lift**
8. **Alveolar ridge distraction osteogenesis**
9. **Timing of extractions, grafting, implant placement and prosthesis**
10. **Conclusion: Long term problems with Implants in Grafted Tissue**

1. Introduction: concepts, principles

The majority of implants can be confidently and safely placed in most alveolar positions without the aid of bone grafting. This usually requires adequate healing, good alveolar bone health, good periodontal conditions, good oral hygiene, and sometimes a little bit of luck. In these situations most implant therapy is rather straightforward. It requires good knowledge of the proximity of adjacent teeth, roots and regional anatomy; proper inter-dental and inter-arch distances; and, ideal angulation of implant placement in order to obtain appropriate abutment and crown restoration shape and position. Implant success is directly correlated to the quantity and quality of bone available in the alveolus.

Oral maxillofacial surgeons are constantly faced with the management of cases that fall outside of this ideal circumstance. Very often after the extraction of maxillary and mandibular molars the alveolar ridges are insufficient for the placement of implants. Furthermore areas along the anterior alveolus in both the maxilla and mandible develop extremely thin ridges over a period of time. Bone grafting of the maxillofacial complex is an essential and crucial role for oral maxillofacial surgeons to help prepare the alveolus for ideal implant placement. The rigors that can be obtained with excellent occlusal, aesthetic and functional results can only be obtained by placement of the implant in an ideal position. In the early days of implant therapy it was sufficient merely to achieve implant integration at whatever cost regardless of position. This placed significant challenges and stresses on the prosthetic rehabilitation of sometimes even the simplest case. This concept of "put the implant where the bone is" is no longer acceptable. Implants need to be prosthetically driven – that is place the implant which will provide the best functional and esthetic position of the crown.

Current therapy using bone grafts in the maxillofacial complex allows for the augmentation of deficient bone sites with healthy and adequate volume of alveolar bone in order to place implants in precise positions producing ideal functional and esthetic outcomes.

Quick Review of Materials:

Autograft (synonymous with autogenous graft): Tissue transferred from one location to another within the same individual.

Allograft: A graft between genetically dissimilar members of the same species.
- Fresh or fresh-frozen bone
- Freeze-dried bone allograft (FDBA)
- Demineralized freeze-dried bone allograft (DFDBA)
- Dentin
- BMP Growth Factors

Xenograft: A graft taken from a donor of another species.
- Bovine
- Porcine
- Coral
- Equine

Alloplast: Inorganic, synthetic, or inert foreign material implanted into tissue.

Hydoxyapatite
Bioactive Glass
Tricalcium Phosphate
Calcium Hydroxide

Material	Osteoconductive	Osteoinductive	Osteogenic
Autograft/Autogenous	Yes	Yes	Yes
Allograft	Yes	Maybe	No
Xenograft	Yes	No	No
Alloplast	Yes	No	No

2. Timing of implants and grafting:

The timing of the placement of **implants** can be either:
-immediately at the time of tooth extraction; (immediate) ie socket preservation
-2-3 months after the extraction of teeth; (Delayed Immediate); or,
-many months/years in edentulous spaces (Delayed).

Do not confuse these terms with the timing of implant placement after bone grafting:

The timing of hard tissue grafting for the purpose of implant placement is divided into 3 stages:
A. Socket preservation of extracted dental sites for future implant placement
B. Immediate alveolar ridge reconstruction with guided bone regeneration at the time of implant placement
C. Ridge reconstruction (alveolar or segmental) in previously edentulated sites followed by a 5-7 month healing phase to allow for bone consolidation prior to implant placement.

i. Socket preservation
This is very commonly done in patients who will undergo implant therapy after the extraction of teeth. This is usually only done if future implant placement is performed but oftentimes can be done as well to maintain alveolar bone height even underneath the pontic for acceptable aesthetics and periodontal health. Socket preservation is complex as the literature and best practice patterns have not been firmly established. The current benefits, techniques, materials, sequencing, are extremely varied and the discussion of this would require further a few more hours of lecture but is also a clinical decision that will be covered in your clinical exposure in Oral Surgery.

Current socket preservation techniques generally involve alloplastic materials and the use of bioresorbable membranes with the aim of producing healthy alveolar ridges in the absence of adjacent periodontal disease. In general, the alveolus is left to heal for approximately 10 weeks to 16 weeks prior to the placement of implants. The length of time is dependent on the site and the requirement for subsequent grafting. For example, it is common practice to extract teeth in the anterior maxilla with site preservation and then 10 weeks later open flap placement of implants with secondary ridge reconstruction and membranes being placed in order to maximize gingival and alveolar bone height. This is commonly done in the anterior regions to maximize the healing and availability of attached keratinized tissue.

A common clinical example is the extraction of the lower first molar. Site preservation material may be placed if there are inadequacies of the supporting alveolar walls. Then this area is allowed to heal for 4 months. The placement of the single implant at this site is done when the alveolus is completely healed from a bony perspective.

The issue of implant placement timing is important. After bone grafting, the grafted material will mature, calcify and heal (a process known as CONSOLIDATION) and this usually reaches its peak healing at about 16-20 weeks and then slowly starts to subside. Eventually the bone turnover process continues and sometimes resorption will begin on the graft at about 8 months. It is not infrequent for grafted sites to completely lose all their transplanted bone even up to 1 year after grafting. A review of Wolff's law about bone physiology will support this phenomenon. In the process of **informed consen**t, your patients need to understand that there is a time frame and a window of opportunity to place implants. If your patient is not interested in an implant, you need to be able to educate them about the loss of the ridge and its negative consequences should they wish to have an implant later in their life.

Final note on socket preservation: it does not need to be done in ALL extractions. Practitioners need to be aware that this is not always necessary and it can produce unnecessary costs and excess morbidity to patients. An extracted premolar tooth with completely healthy alveolar walls does not need site preservation. Alveolar health and healing after 16 weeks will allow for placement of an implant without the need for bone grafting. Careful evaluation of the literature with continued surveillance of marketing and the promotion of bone materials by a large number of companies should not dissuade you from proper and appropriate treatment planning.

ii. Immediate alveolar ridge reconstruction with guided bone regeneration at the time of implant placement

In certain circumstances the amount of alveolar bone height, width, and health may be adequate enough for the placement of an implant to obtain proper primary stability. The key issue here is **primary stability** of the implant placed in the bone and is generally acknowledged to be at least an insertion torque of 35ncm. Sometimes there is a small volume of bone that may allow for the placement of an endosseous implant and very good stability at 35ncm; however, the hard and soft tissue architecture will require augmentation of bone in all 3 dimensions in order to ensure proper alveolar bone and gingival support. This is commonly performed in the anterior maxilla 10 weeks after the extraction of an incisor. This allows the practitioner to place the implant, add layers of allogeneic bone, alloplastic bone, membranes, and repositioned gingival tissue which maximizes the healing potential. Obtaining ideal bone and gingival height can be obtained by doing all these procedures at the same time. Controversy exists over the need to place temporary crown at the same time. In general, an implant with over 30 Ncm of torque can withstand the placement of an immediate abutment and a temporary crown. This can be done in situations where the ability to shape the gingiva can be prosthetically controlled. This sometimes results in better esthetics. However, it is dependent on healthy and abundant keratinized tissue. If this is lacking then a two staged approach may be better and then it is necessary to bury the implant in order to allow for the formation of extra keratinized tissue which will allow greater manipulation at a later stage.

Implants love bone first and then they love keratinized tissue. Healthy keratinized tissue increases longevity of implants and a decrease the incidence of peri-implantitis/peri-mucositis.

Immediate Implant Placement: The trend to extraction, with immediate implant placement, with immediate crown loading is an attractive and intuitively beneficial procedure. Research is showing that in order to confidently employ this technique ideal conditions (torque insertion >35ncm, good bone height, good keratinized tissue, good periodontal health) do not always occur. Particularly in the aesthetic zone - a delayed treatment with maximizing keratinized tissue healing is often a *better* course of treatment. This is also important because it has been shown in long-term implants that immediate extractions with immediate implant placement produces reduced height of alveolus after 5-10 year period. However, this option should not be abandoned. If there is a small root, that is non-infected, but can be removed without damaging the bone, and having been ideally placed implant in an ideal angulation then immediate post extraction placement should be given a consideration. But this can be the most challenging decision facing even the most experienced surgeons.

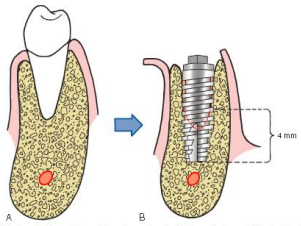

Figure 15-1 Implants placed in fresh extraction sockets must have 4 mm of precise fit along apical aspect of implant. Implants should be countersunk slightly below the crest of bone. Gaps between the implant and facial socket wall are most often grafted with autogenous or allogeneic bone, bone morphogenetic protein (BMP), or both.

iii. Ridge reconstruction of edentulous sites prior to implant placement. This is followed by a 5-7 month healing phase to allow for bone consolidation prior to implant placement.

This is the most common scenario faced by OMF Surgeons. Frequently it may be due to a large defect created iatrogenically or due to extensive disease, a failed implant case, a failed bone graft case, or other challenging conditions with little or no basal bone for support. The goal is to restore the alveolar bone to an ideal height, width and position. A typical scenario would be the edentulous maxilla with a thinned anterior alveolar ridge with inadequate bone with to place an implant. Another scenario is the atrophic maxilla that is retruded posteriorly. The patient is now in a Class III skeletal position that places great stress on the dentist placing the implant and the dentist restoring the implant.

A variety of techniques have been described, proposed, experimented on, but none can surpass the gold standard of autogenous bone grafting to most areas. The most common area of harvesting bone for larger sites is iliac crest bone. Later in the lecture harvesting of this bone will be explained. You will be exposed to a variety and significant number of different proposals in order to increase the volume of bone in the maxilla. From titanium cribs, porcine grafts, human freeze-dried block grafts, bovine blocks, gels, putties, powders, and particles. There have been many types of tissues and materials proposed and experimented on with variable success.

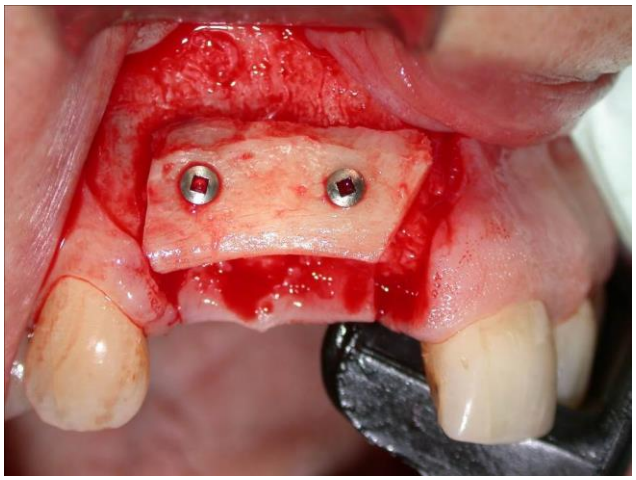

However, in most circumstances, autogenous bone remains the ideal material because of its many properties (osteoconductive, osteocinductive, osteoregenerative). A patients own bone (autogenous) is obviously the perfect match with no immunoreactivity (which is a problem with all the other materials). The quality and type of bone is similar, rejection is significantly decreased, and infection rates of these partially vascularized grafts is also significantly lower especially when placed on an appropriate and healthy vascularized bed. Another graft you will be exposed to but has targeted therapies is the use of vascularized grafts. These free tissue composite transfers are harvested with here blood supply form the fibula, radius, scapula. These are used to reconstruct large segmental mandibular defects and this will be covered briefly in another lecture.

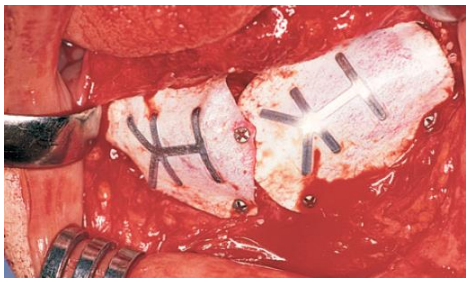

Nonresorbable membrane placed over grafted bone

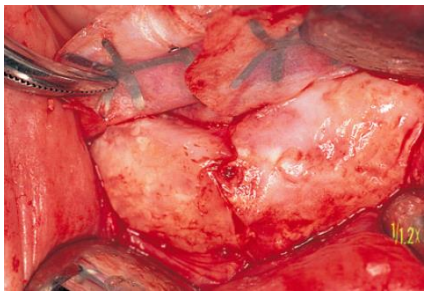

5 months later

Implants in place

The specifics of bone biology and the different types of graft have been covered in the previous lecture and review of these materials may be beneficial in order to understand the continued discussions that follow.

3. Guided bone graft augmentation/regeneration (GBR)

The greatest challenge in grafting and transplanting bone to the maxillofacial region is the loss in the graft or in the volume of the graft. About 3-5% of the time, grafting procedures will fail and mostly due to infection. Then if the graft takes there is an overall loss in its volume as it consolidates. This is a critical item to review when dealing with **consent** with a patient regarding grafting.

The loss of volume of bone is directly related to the source. In general cancellous grafts from all sources will reduce in size approximately 30%. Cortical grafts from the cortex of the iliac crest or the calvarium will resorb less than cancellous bone. However cortical grafts will have a higher failure rate but to infection because of their lack of cellularity. That is why the corticocancellous block of the iliac crest provides the highest success because it maintains a specific volume due to the cortical bone and provides a substantial amount of cellular material in order to allow future bone growth. Corticocancellous grafts are a combination of;
1. cortical bone which provides structure, has similar embryologic origin as mandibular bone, and they contain a larger amount of BMPs and
2. cancellous bone which is more cellular, has greater vascularity and volume

A significant amount of the resorption of bone occurs due to fibrous ingrowth from the overlying gingival tissues. The worst scenario is epithelialization of grafts which can eliminate the bone and present as a mass of granulation tissue. So, in order to minimize this membranes, tissues and barriers are placed.

Some of the membranes include: periosteum, collagen (bioguide), dura membrane, human skin (alloderm), e-PTFE (Gortex), memlock, Titanium mesh, collatape, surgicel, and glues.

The term 'guided bone regeneration' simply means that a barrier is been placed to reduce non-osseous ingrowth of either fibrous tissue or epithelial tissue. These membranes will allow the underlying graft bone to consolidate without insults of invading epithelium or fibrous tissue or pathogens. Resorption of bone is also decreased. The membranes are usually also porous to beneficial nutrients and gases. A misconception however lies with the *de facto* use of collagen barrier membranes as the only source of membranes. The most common and best membrane is the patient's own periosteum. If the patient has adequate periosteal coverage that is healthy this is all that is needed to overlie the graft. However if the gingival bio type is thin with an inadequate periosteum and poor periodontal condition adjacent to the site then membranes are essential



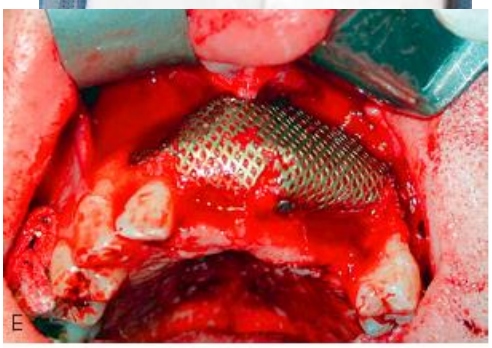

.

There are many types of membranes available. The majority are collagen bovine based that have a resorption of 8-12 weeks. This is adequate enough to stop unwanted tissue (usually epithelial) from growing into the bone graft yet the membranes are porous enough to allow the vascularity to extend superficially through to the gingiva. One of the most effective membranes that remains is Titanium mesh. This material can be shaped in three dimensions and hold the bone in a specific shape and position while keeping the gingiva superficially. Titanium mesh oftentimes is also used with collagen membrane over top in order to facilitate flap exposure at the time of implant placement (especially when the gingival biotype is thin)

The amount of time required in order to allow for these guided tissue regeneration cases will vary from for 3-6 months. This depends on the size of the graft, the location of the graft, the materials used, and close follow-up to see how the patient has been healing. Any dehiscence or infections along the way will obviously delay implant placement or may require further grafting.

Complications include:
Dehiscence
Infection
Resorption
Unequal consolidation
Mobility of graft leading to failure
Infection of membranes leading to loss of membrane and decreased volume

4. Harvesting Bone:

i. **Iliac Crest Anterior and posterior**
ii. **Costochondral**
iii. **Intraoral: ramus, symphysis, tuberosity**
iv. **Tibial Head**
v. **Calvarium**
vi. **Other: Platelet Rich Plasma/Traps/Filters/Scrapers**

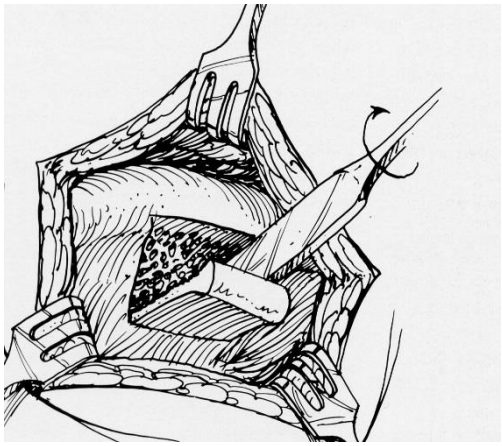

i. The anterior iliac crest and the autologous bone derived from this area has made this technique the gold standard for harvesting good quality bone for numerous Maxillofacial, orthopedic, plastic and neurosurgical applications. The ease of harvest, the low morbidity, the ability to work in teams, and the modest amounts of bone obtainable have all lead to its great popularity.
The amount of bone that can be harvested is quite variable. In atrophic elderly patients there may be very limited cancellous bone. It is estimated that up to 50cc of bone can be obtained.
COMPLICATIONS: Infection, hematoma, paresthesia, scar formation, pain, gait disturbance.
Advantages include rapid harvesting of bone in 2 teams, very low morbidity which can be minimized by limited periosteal stripping, and it is sufficient for most sinus lifts, anterior augmentation and a general rule of thumb is that it can cover any defect less than 5 x 5 cm
The only disadvantage is that there can be a certain amount of "surprise factor" where the amount of bone may be inadequately low. This can only be ascertained with preoperative CT scans but this is not often performed.

I-b. The posterior Iliac Crest is useful when significant volumes of bone are required such as amounts required for bilateral sinus lifts or mandibular continuity defect reconstruction.

- Provide a fair amount of cortical bone for onlay grafting but greater amounts of cancellous bone are available with this approach.
- Literature suggests that patients experience significantly reduced patient morbidity as compared to anterior approach to the iliac crest.
- Predictably better quantity and quality of bone when compared to the anterior approach (approximately 2-2.5 times more bone than the anterior approach).
- May take slightly longer to perform as the surgery has to be performed in a prone position. Therefore, patient must be turned prior to proceeding with intraoral surgery.
- Will not allow for a two-team approach.

Trephines. Many surgeries in the maxillofacial area require small amounts of bone. It is well established that the ideal grafting material is cellular cancellous autografts of bone. The ilium is ideal because of its general low morbidity and variable quantity.

Trephines were first introduced by the renal physiologists to sample marrow bone for bone quantification analysis. The trephines developed were quite varied and sampled different sizes of bone. Elevation of musculoperiosteal flaps to gain access to the iliac crest may result in significant postoperative morbidity, including pain, hematoma, delayed ambulation, and increased length of hospital stay; this is true whether an antero-medial, antero-lateral, or posterior approach is used. The current trend in many surgical specialties is the development of minimally invasive techniques which are designed to minimize post-operative morbidity. This trend can be extended to the procurement of autogenous bone by means of a trephine. Several descriptions of various techniques are reported which attempt to minimize morbidity. The safety and yield of trephines has been well reported with respect to their use as a biopsy tool and a few reports have shown equivocal success for the procurement of bone for maxillofacial purposes.

ii. The **costochondral graft (CCG)** is a common method to construct/reconstruct the ramus and condyle unit because it provides:

1. Autogenous material without the possibility of a foreign body reaction
2. A cartilaginous articulating surface
3. A permanent bony union and biologic remodeling with response to function
4. Growth potential.
5. Minimal donor site morbidity

Many reports have documented the rationale for use of the CCG for construction and reconstruction of the ramus condyle unit (RCU). The CCG is a growth center and it adapts to function. Initially its morphologic character does not resemble that of native condylar cartilage; however, it remodels over a period of time and eventually becomes similar to native condylar cartilage. The growth of the CCG is controlled by intrinsic (growth centers) and or extrinsic (functional matrix) factors.

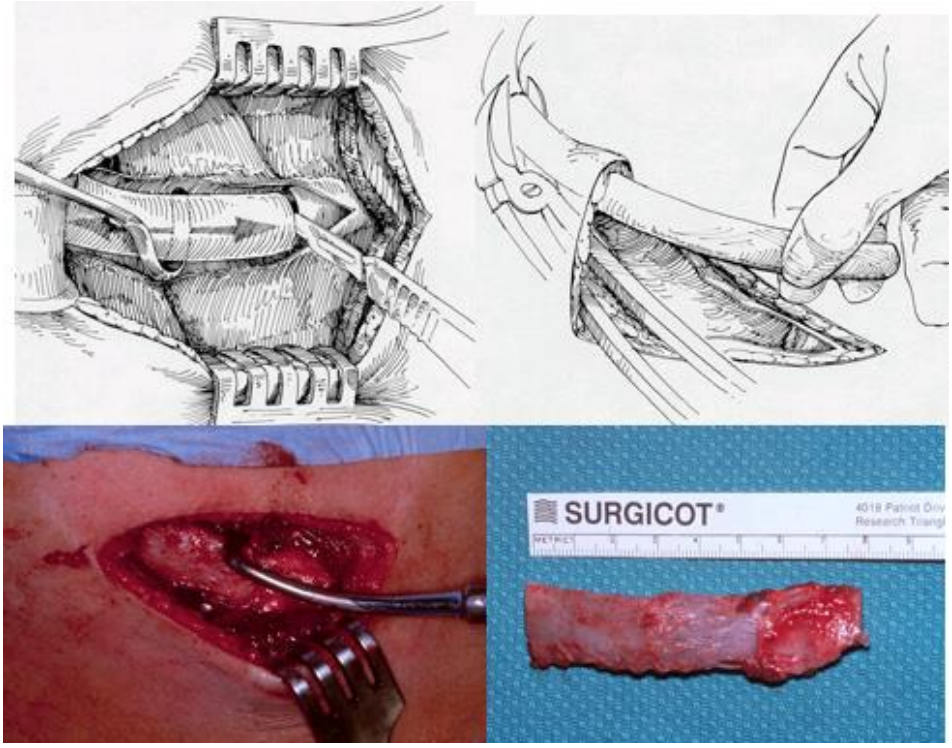

In children CCG has been performed for the correction of jaw deformities, growth disturbances, syndromes and other abnormalities arising from intra-articular fractures, arthritis and other arthritides. In adults, ankylosis, osteoarthritis, neoplastic diseases, post-traumatic dysfunction and osteomyelitis have been indications for RCU reconstruction with CCG. The grafts are applicable to the entire spectrum of TMJ abnormalities, both developmental and acquired, and have become internationally popular despite various difficulties. However, for the use of common implant therapy the costochondral graft is not often used in isolated defects but can sometimes they used in compound defects in conjunction with other bone materials. The boney portion tends to be very soft and pliable so it does not maintain its shape as well as other cortical blocks.

iii. Intraoral sources:

Mandible: Sometimes continued locations to harvest bone will include the body of the mandible itself. It is not unusual to harvest bone from the symphysis if grafting the anterior mandible. **Symphyseal bone grafting** is a method of obtaining a solid block of cortical bone with very little cancellous cellular marrow. This presents as one of the disadvantages of using this bone as its vascularity is quite compromised. Secondly the harvesting of the bone is challenging because reflection of the mentalis muscle is required. Delicate surgical skills are required to remove the outer cortical layer of bone. Sometimes the bone is fused just inferior to the apices of the incisors which will not allow for a clean unshelled piece. Mandibular fractures have occurred. The symphyseal region tends to heal very slowly with long-term swelling and discomfort.

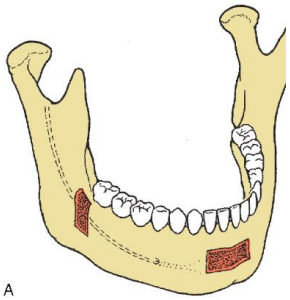

A second and more common site to harvest bone is the **mandibular ramus in the retromolar** area. A clean solid piece of buccal bone can be removed and easily manipulated into shape and grafted in a variety of locations. The difficulty with ramus harvesting is that it is technique sensitive and care needs to be maintained because on unshelling the bone, the inferior alveolar nerve is oftentimes exposed and care needs to be applied to the

nerve. It shares similar characteristics with symphyseal bone in that it has low vascularity but it does sometimes unshell with some cancellous marrow which is beneficial.

Maxilla: **Tuberosity** and shavings for zygomaticomaxillary buttress area are sometimes used for very small volumes of bone and generally if needed in an adjacent area. The volumes are poor and the quality of bone is not that significant. Tuberosity bone is simple to harvest with a rongeur but the bone compresses easily into small volumes and it may be necessary to harvest from both tuberosities in order to get a sufficient volume of bone to use in augmentation procedures.

iv. Harvesting bone from the **Proximal Tibial Head (PTH)** is a simple, rapid, effective and safe method to obtain moderate amounts of good quality cancellous bone. The most beneficial aspect of this technique is its ease of applicability in the outpatient, ambulatory, in-office setting. Surprisingly most think that the tibial head is small and would provide little bone. Indeed the tibial head is almost the same size as your fist and does contain 5-8cm of cancellous bone (Lateral to medial). Or about 3X3 cm volume. It is however a delicate procedure that can lead to gait disturbances if the tensor fascia lata tendon/muscle is disturbed. As well, the older the patient is the fattier the marrow becomes and these yield poor quality bone.

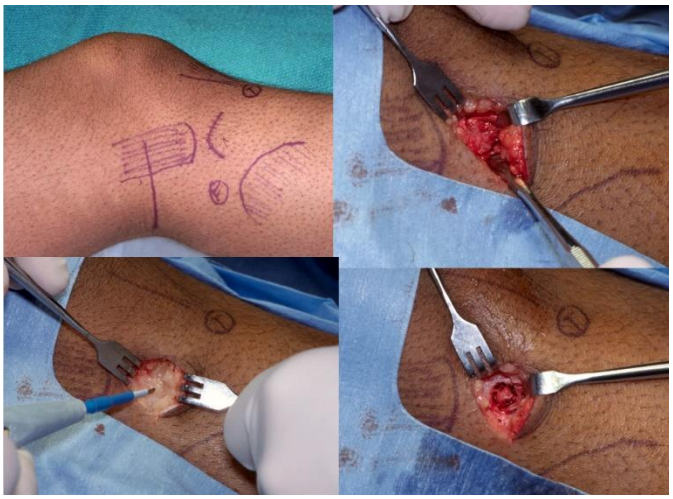

v. The **Calvarium** represents the most reliable and predictable source of membranous bone available for harvesting in the Cranio-maxillofacial skeleton. The anatomy of the region is well known to most OMF Surgeons and with a few precautions these grafts can be harvested safely. These grafts are dense, largely cortical pieces of bone harvested from the outer table or diploë of the cranium. The bone is morphologically flat and of high strength, resistant to bending and deformation, depending on its thickness. Their application includes use in surface defect contour correction, orbital floor reconstruction, and glenoid fossa reconstruction.

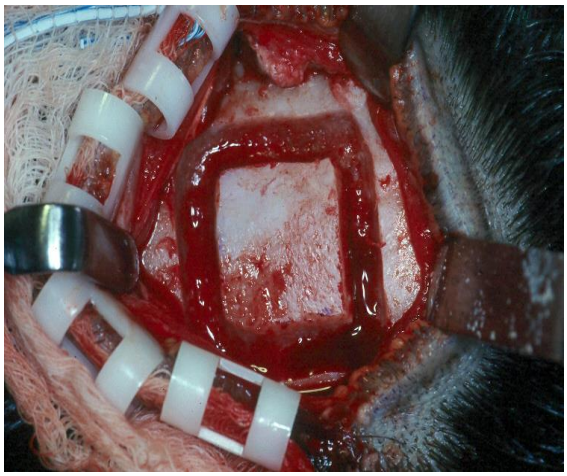

There is little value in using such grafts for alveolar bone grafting or dental implant site preparation, as these grafts are largely brittle cortical bone and split easily when rigid fixation screws or implants are placed.

vi. Other: Platelet rich plasma: PRP has received significant amount of attention over the past 20 years due to some inherent beneficial products with regards to healing and bone regeneration (ed. "potentially"). It also gained significant notoriety in its use for sports medicine and miraculous healing of all sorts of conditions including hair loss, tendinitis, skin rejuvenation and colorectal surgery.

Growth Factor	Primary Functions
Epidermal growth factor	Regulation of cell proliferation, differentiation, and survival
Insulin-like growth factor	Key regulator of cell metabolism and growth Stimulates proliferation and differentiation functions in osteoblasts
Platelet-derived growth factor	Major mitogen for connective tissue cells and certain other cell types. Promotes the synthesis of collagen and structural proteins
Transforming growth factor (ie, alpha, beta)	Regulation of cell proliferation, differentiation, and apoptosis Induction of intimal thickening
Vascular endothelial growth factor	Regulation of angiogenesis

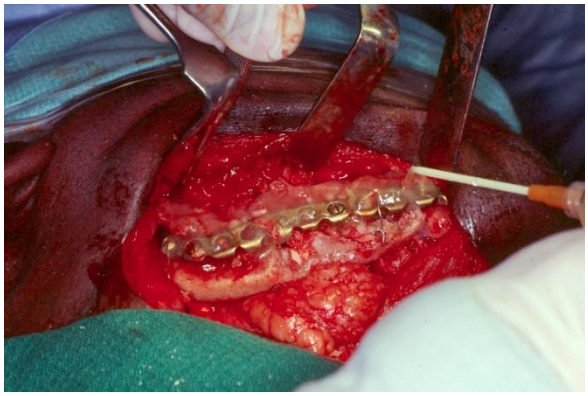

PRP is a layer of platelet rich plasma that occurs when patient's own blood is spun in the centrifuge for specific period of time. Various machines can be utilized to both extract blood and centrifuged the bone. And then the PRP layer is removed and mixed with bone components of the graft. The nature of the PRP itself produces a gelatinous mass that is easily moldable and therefore has inherent suitable handling characteristics. The major ingredient that is reported include the deposition of platelet derived growth factor, transforming growth factor beta, fibroblast growth factor, insulin growth factors, epidermal growth factors and is well connective tissue and vascular endothelial growth factors. For these reasons it is understandable why this product is attractive. Studies show good initial healing with decreased bleeding and hematoma formation in the short term but in the long-term, up to 1 year post surgically, there is no discernible difference between bone augmented with or without PRP. Many reports and reviews in the scientific literature are viewing PRP to be nothing more than a "Profit Rich Placebo".

vi. Other: Suction Trap Bone/Drill debris collection/Scrapers: Not an ideal source. These rely on the shavings, powder, and dust particles that flake off intentionally or unintentionally from mechanized instruments or drills. Some have devised small scalpel scrapers (imagine a mini paint scraper from Canadian tire). Although they can seem to produce a fair volume of bone it tends not to be so great for augmentation. Drill bit shavings can be used to fill small voids but in general this bone is inferior because it is macerated and overheated.

5.Mandibular Augmentation

The requirement for augmenting bone is most notable in the posterior mandible when a sagittal defect occurs after lengthy period of edentulousness. These defects are difficult to augment for a variety of reasons:

1. The remaining alveolar bone height in the basal bone is small and the inferior alveolar nerve generally courses centrally so that manipulation of this bone and the application of rigid fixation will sometimes be complicated by the presence of the nerve.
2. The tissue is superiorly repositioned and limited and this places a stretch and a challenge in order to get primary closure.
3. The defect needs to be over contoured by 30% to allow for shrinkage during bony consolidation phase.
4. The bone graft material of choice remains that of iliac crest autogenous grafting allowing for the best vascularity. Bone out of a bottle or plastic wrapper will not work in this area. Innovative tunneling and pocket sliding bone grafts are sometimes performed where a small incision is placed at the premolar site and a contoured block of cortical cancellous iliac crest is slid through the pocket onto the alveolar ridge and then fixated in place.

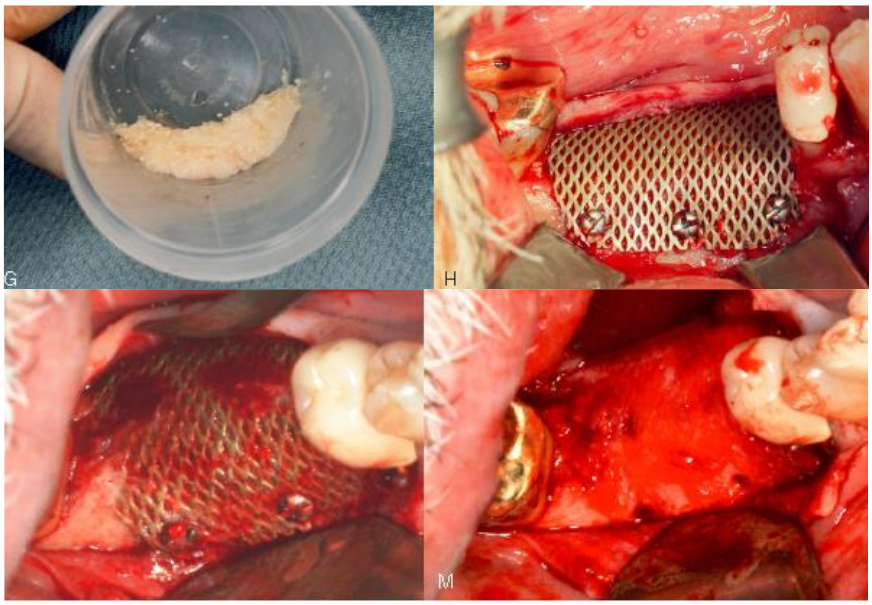

Probably the most common and successful method is the use of a titanium mesh as outlined in new textbook. After 5 months of healing and the application of mesh and membrane the underlying alveolar ridge can be adequately reconstructed. Placement of implants and then proceeds without complications.

In the thin atrophic mandible, sometimes circumstances require the use of **nerve transpositioning.** This technique is generally performed under general anesthesia in the inferior alveolar nerve is dissected from its bony housing using fine reciprocating saws or piezoelectric saws. By moving the nerve laterally, implants can be placed without fear of damaging the nerve complex. After the implants are placed the nerve is gently repositioned. However, sensory deficits still persist and need to be explained to patients.

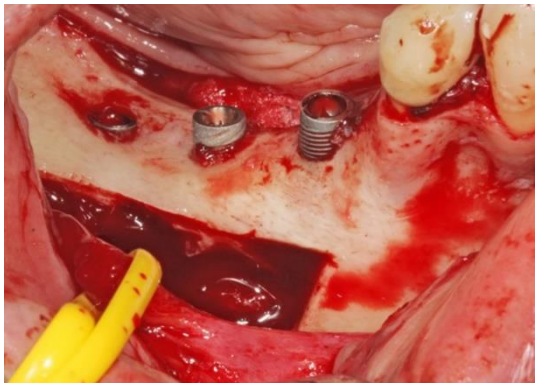

Another but infrequently used technique to augment bone in the anterior mandible is the extraoral grafting with immediate implant placement of the area of the mandible bounded by the mental foramina. This is commonly referred is the **tent pole technique** and has proven to show excellent success in both short-term and long-term implant viability. Furthermore it also augments vertically the anterior face and cases are shown both in lecture and your textbook.

This consists of placing for implants in the remaining basal bone of the mandibular ridge. The implants are at least 10 mm in length. The remaining height of implants that are not embedded in bone are covered by iliac crest bone that has been morcellized into tiny fragments. Because the oral mucosa is not invaded the use of membranes is not required because the periosteum is intact. The only disadvantage of this technique is that it needs to be approached from an extraoral incision that will leave a visible scar but in general this can be hidden in an existing mental cervical fold.

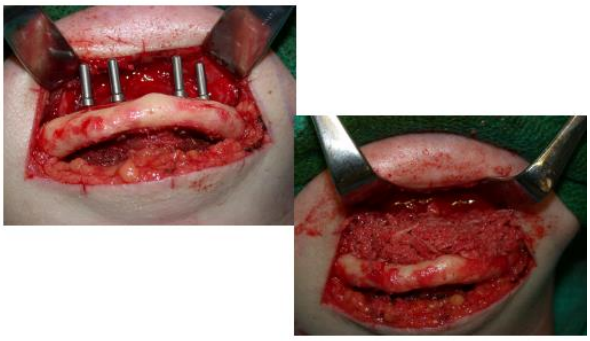

6. Maxillary Augmentation

Unlike the mandible, *vertical* augmentation of the maxilla has been proven to be a challenge for maxillofacial surgeons. *Lateral* augmentation using a variety of materials: Iliac crest, titanium mesh, and other membrane and tenting techniques are usually quite successful in the maxilla because of the good vascularity. Furthermore, submucous vestibuloplasty or vestibuloplasty with periosteal releases can be performed allowing for the tissue to be brought over the grafted sites with good primary closure.

However, *vertical* augmentation inferior to the bony crest has not produced adequate results primarily because of the stiffness of the palatal tissues and the challenge of vascularity. So the solution to this is augmenting vertically superiorly via the existing maxillary antrum (sinus lift) or piriform aperture (nasal floor augmentation)

Lateral or buccal augmentation works well. The timing before you can place an implant is approximately 5-6 months after grafting. Radiographs *MAY* be required to ascertain that bone consolidation is complete. These lateral augmented grafts will allow for adequate buccolingual width. The placement of implants (inclination, angulation, axial position) will then be uncompromised and ensure proper occlusion of the future crowns.

6B. Split-ridge technique: An augmentation procedure to increase the width of a narrow residual ridge by surgically splitting it or expanding it with a series of osteotomes of increasing diameter. Challenging, difficult, very limited, poor option. There is much controversy regarding this technique and is generally not utilized at higher levels of reconstructive cases.

7. The Sinus Lift

The sinus lift is perhaps the most common bone augmentation procedure performed in complex implant treatment. The pneumatization of the sinus after the extraction of maxillary molars is frequent. Maxillary alveolar bone atrophies significantly faster than mandibular bone and the added air pressure from the pneumatization increases this loss of bone significantly. Approximately 50% of maxillary first molar implant sites will require some form of sinus augmentation. The most popular form of sinus augmentation remains that of the sinus lift. This simply refers to the lifting of the delicate schneiderian membrane superiorly and the placement of bone in the gap created between the maxillary alveolus and the membrane. After 4 to 6 months healing and depending on the type of grafting material used, implants can be placed with very good primary stability and future crown placement. The most successful materials used will depend on the status of the membrane and the coverage over the alveolus. If perforations occur in the schneiderian membrane these need to be covered with a resorbable collagen membrane.

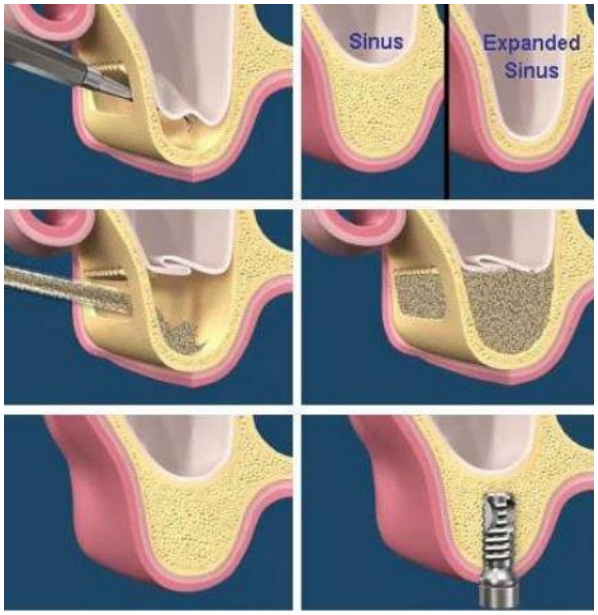

The sinus membrane is oftentimes exquisitely delicate and it may be common for some practitioners to place a membrane all the time. A second variable is the lateral wall and its position and coverage. If the alveolar ridge is deficient in buccolingual dimension vertical augmentation may be required and therefore resorbable membrane may be required.

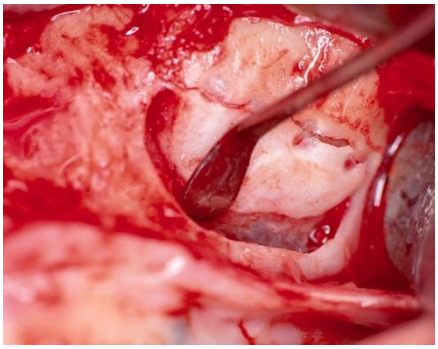

The materials used have varied tremendously over the past 20 years. The gold standard and the most successful remains that of a combination of autogenous bone mixed with a longer resorbing alloplastic type of material. Another popular and effective method is the use of decalcified freeze-dried bone and a putty matrix that allows for easy workability.

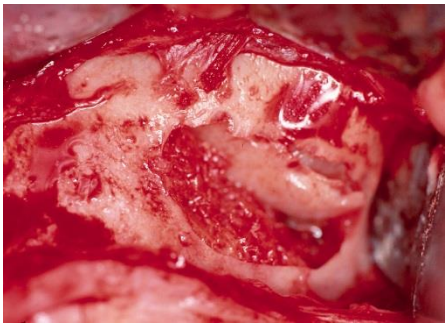

8. Alveolar ridge distraction osteogenesis

This has been experimented on over the past number of years because of the success of distraction osteogenesis in lengthening limbs and growing bone. The concept, history, physiology, indications, technique, and use of distraction osteogenesis will be covered in detail in your fourth-year class of facial reconstructive surgeries.

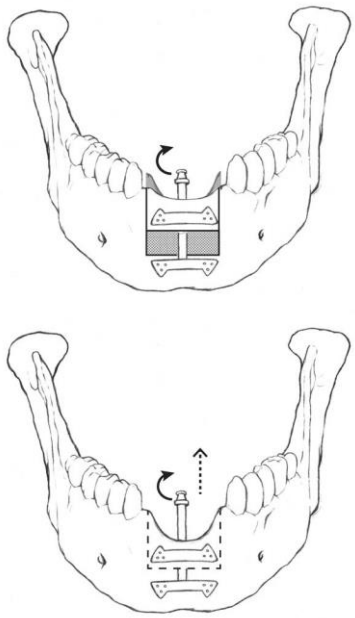

To summarize, a distraction device is placed over a segmented portion of bone and the patient turns a screw every day that lengthens the bone and displaces it superiorly or inferiorly whether in the mandible or maxilla. The callus that forms in between these distracting segments will ossify over a consolidation phase of 4-5 months. In general, distraction only takes place over a 2-3 week period. This very technique sensitive procedure has not produced the most satisfying results because of failure of the mechanics or infection, but in extremely atrophic cases this sometimes can produce incredible results.

9. Timing of extractions, grafting, implant placement and prosthesis fabrication

Sometimes the greatest challenge in implant therapy is the timing of treatment. The variability of the conditions of the extracted tooth, the underlying bone quality and quantity, the placement and size and angulation of implant, the future position aesthetics and occlusion of the final crown all play a role in the decision-making associated with implant placement.

The best scenario deals with a fractured uninfected small premolar tooth which can be extracted without damaging the alveolar bone and the placement of an implant immediately with immediate temporization and final crown placement at 6 weeks. As discussed above this is a unique situation that does not often present.

The other extreme is a bony defect created by post ablative cancer surgery requiring a vascularized or nonvascularized composite graft to restore a segment of bone of the maxilla and mandible. This requires 5-7 months of healing in order to allow proper bone consolidation. Implants are placed in this bone which tends to be slightly softer than nascent basal bone and will require a greater length of integration time of approximately 3-6 months. Following this are the challenges from the prosthetic point of view in restoring compromise sites and all this treatment can take up to a year.

The vast majority of timings will follow in between these 2 extreme scenarios. Most common situation would be for the extraction of an infected or fractured molar requiring some minor site preservation with a healing time of 16 weeks prior to the placement of an implant which will require another 8 weeks of integration time followed by 2-3 weeks of prosthetic manipulation prior to the insertion of the final prosthesis.

10. Conclusion: Long term problems with Implants in Grafted Tissue

Contemporary implant treatment cannot be successfully rendered without the aid of bone grafting. Compromised implant placement, inadequate implant size, poor implant angulation, and inappropriate prosthetic placement with compromised loading (re: occlusion) is not an acceptable treatment. Implant therapy is a costly intervention from both an economic and social standpoint. Inappropriate and quick fix methods are detrimental in this oftentimes difficult and challenging treatment modality. The public image and perception of dental implants is quite poor.

If sequenced properly, with proper attention to bone health and quality, the longevity of implants is proportionately augmented. Most implant and graft complications occur within the short-term (1-2 months). Some complications can occur even up to a year later. Unfortunately, the complication rate with bone grafts and implants does vary between practitioners – there is a 3-5 time higher failure rate/infection rate when comparing specialists and generalists. This should come as no surprise as the experiences between the two groups are large.

Another long-term problem that is consistently seen is the vertically augmented mandibular bone with grafting regardless of material used. Over time there seems to be a reduction in the height of the grafted bone up to the level of the nascent basal bone regardless of patient care, hygiene, prosthetic loading, and prosthetic condition. Consideration should be given to nerve lateralization but this is a difficult and specialized technique.

Adding to this difficulty is the placement of implants and grafting in the esthetic zone. If implants are placed immediately without proper bony support, good keratinized tissue, ideal occlusal loading and perfect hygiene there will in time result in an unaesthetic implant due to metal show and gingival destruction and this may occur slowly over a period of time and no secondary grafting will help.

A note to remember is that once an implant is integrated – there are no grafting techniques available that will allow for subsequent bone growth on exposed implant threads. Grafting is still performed to eliminate periodontal pockets and improve gingival support, but you will NEVER get new bone to integrate onto an already integrated implant.

Notwithstanding the above issues, bone grafting prior to or in conjunction with implant placement is an essential and viable modality that can produce aesthetically and functionally pleasing results with good long-term stability in most cases